

Tuberculosis Detection in Chest X-Ray Images Using Deep Learning Methods

Mr. Athukuri Prasad
Scholar, JJTU
mailsofprasad@gmail.com
Dept. of ECE

Dr. Alok Agarwal
Internal Guide
alokagarwal26aaa@gmail.com
Dept. of ECE

Dr.Ch. Rami Reddy Research
Co - Guide
crrreddy229@gmail.com
Dept. of EEE

Abstract: Deep learning is one of the 10 most revolutionary technologies in data analysis. Data representations with several layers of abstraction may be learned using deep learning. Visual object identification benefits most from deep learning. Tuberculosis (TB) identification in X-ray pictures may be solved by using deep learning. For radiologists who are in limited supply, these new tools may help enhance TB diagnosis and treatment. CAD4TB, qXR, and Lunit INSIGHT are three examples of deep learning-based software systems that have been used to identify abnormalities in chest X-rays (CXRs). CAD4deep TB's learning-based software uses a heat map picture to highlight the anomalous area. There are 15 anomalies that the qXR programme may identify from abnormal chest X-rays. There are 10 anomalies that may be seen on the chest radiographs using the Lunit INSIGHT CxR programme. There must be a human observer to verify the usage of deep learning-based computer-aided detection systems (CAD). The receiver operating characteristic (ROC) curve is used to evaluate the accuracy of CAD software. Ethical and scientific standards must be adhered to while using deep learning in medicine.

1 Introduction

The early detection of tuberculosis (TB) is critical for effective prevention and regulation. Poverty, overcrowding in slums, poor nutrition, mental health issues, drug use, and HIV infection all contribute to the high TB prevalence [1]. Poor health care conditions and a shortage of CXR readers may contribute to a widening of the TB detection gap in various countries. Tuberculin skin tests (TST), chest X-rays (CXRs), questionnaires, sputum culture and acid-fast bacillus (AFB) tests are some of the screening procedures used to diagnose TB. The WHO recommends a chest X-ray as a first step in the detection of tuberculosis (TB). In order to diagnose disorders of the chest, radiographs of the chest are required. To identify tuberculosis, an X-ray machine, skilled personnel to maintain the machine, and a lack of specificity by observers

restricted the role played by X-ray pictures. Computer-aided TB detection (CADT) was revolutionised by the introduction of digital radiography [3]. The radiologist's ability to accurately diagnose TB from a CXR is dependent on his or her training.

2 Role of Deep Learning

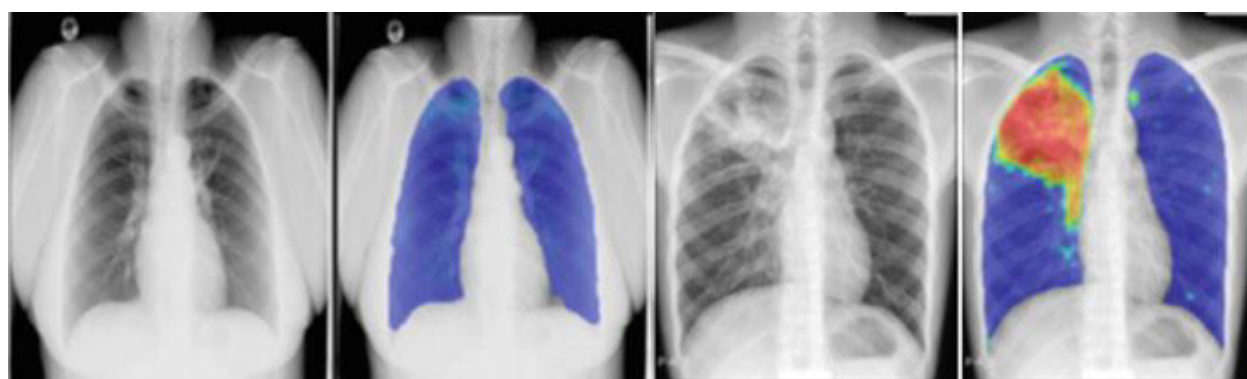Automating medical imaging research and diagnosis has never been easier thanks to deep learning (DL). In radiology practise, it may lessen the strain on radiologists [4]. Deep learning in radiology includes image registration, segmentation, neurological illness diagnosis, computer-aided detection systems for X-ray, CT, mammography, and MRI images, and natural language processing (NLP) for text analysis of reports [5]. To extract characteristics from raw data, conventional machine learning techniques needed a deep understanding of the subject matter. The classifier uses these characteristics as feature vectors in its training process. Patterns in the input might be classified [6]. Because of the vast training data collection and computer power, neural networks and deep learning have become more popular [7]. Automated extraction of features from a raw dataset is possible using DL approaches. Image classification and identification using deep learning-based convolutional neural networks is also employed in CAD systems to identify illnesses from various medical pictures [8, 9]. CNNs are a solid tool for computer vision problems because of their convolutional structure. CNNs and other deep learning approaches are now being used in medical image analysis [10] by medical image analysis organisations. Both the feature extraction and the classifier are components of CNN. Feature extraction in a CNN is accomplished via the use of convolutional layers. As a classifier, fully linked layers [11] may be used.

Listed below are the sections of this document. CAD4TB screening software is described in Section 3 and the various CAD4TB versions are evaluated. There is a short overview of the qXR and Lunit INSIGHT softwares in sections 4 and 5. Sect. 6 describes a TB detection software based on machine learning called TimBre. Sections 7 and 8 wrap up the paper's topic.

3 CAD4TB

Radboud University Medical Center in Nijmegen, the Netherlands, created the CAD4TB programme for screening purposes. The CAD4TB was released by Delft imaging systems and is CE-certified [12]. In order to distinguish between normal and pathological X-ray pictures, the

CAD4TB software is taught using machine learning algorithms and tagged images. An X-ray picture of the chest may be used as an input into the CAD4TB programme. CAD4TB generates an abnormality score ranging from 0 to 100, as well as a heat map showing the image's abnormality areas. Normal or abnormal CXR images are categorised by this threshold value. For the most part, this threshold figure is more than 50 percent. The result of CAD4TBv6 is shown in Figure 1. In [13], the accuracy of screening digital CXR utilising CAD4TBv1.08 for the identification of TB is compared with clinical officers. Different detection technologies such as textural abnormality detection (TAD), shape abnormality detection (SAD), lung field detection, and clavicle detection are combined in the CAD4TB to provide a more comprehensive diagnosis (CD). To limit false-positive responses, a CD system and a TAD system functioning at the pixel level are combined. This results in an image decision. An abnormality score is generated by the SAD system depending on the morphology of the lungs. The final abnormality score was computed by comparing the SAD system score to the TAD system score and summing the results. The abnormality score of a fresh CXR picture was determined using a k-NN classifier trained on texture and shape abnormality scores [14]. According to CAD4TBv1's anomaly detecting mechanism, Figure 2 demonstrates. If you have a fresh CXR image of CAD4TBV 1.08, the procedure is as follows: The unobscured lung area is automatically segmented for the fresh CXR picture using SAD and TAD detection methods;



(a) (b) (c) (d)

Fig. 1 Two example CXRs with corresponding output heat maps using CAD4TBv6. **a)** CXR image with negative TB, an abnormality score of 17. **b)** Corresponding abnormality heat map. **c)** CXR image with positive TB, an abnormality score of 82. **d)** Corresponding abnormality heat map

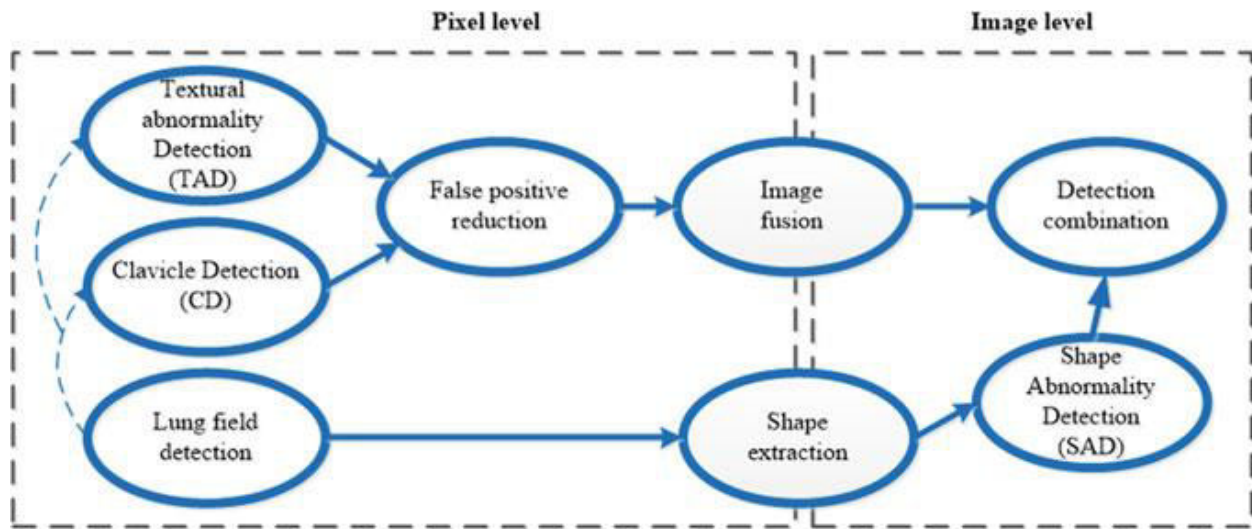


Fig. 2 Combination of detection systems [14]

- The SAD system calculates a shape abnormality score based on lung shapes;
- For a fresh CXR picture, the abnormality score is predicted based on the training data of texture and shape abnormality scores.

For the identification of tuberculosis in a real-world situation, researchers Muyoyeta et al. tested the CAD4TBv1.02 software effectively. CAD4TBv1.02 had been demonstrated to have high sensitivity and poor specificity by the authors. Steiner et al. [17] compared CAD4TB v3.07's chest X-ray screening performance with that of human readers (radiologists). Using automated digital chest radiography (ACR) before the Xpert MTB test was reviewed by Philipsen and Melendez [18] and Melendez et al [19]. Automatic programme CAD4TB version 5 was put to the test in chest X-ray (CXR) screening by Melendez et al. [20]. Support vector machines were utilised as a classifier in CAD4TBv5 to improve performance over prior versions. A comparison of CAD4TB v3.0, CAD4TBv4.0, CAD4TBv5.0 and CAD4TBv6.0 to the Xpert test was reported by Murphy et al. [21]. The sensitivity and specificity of CAD4TB v6 were both over 90%. Although the preceding CAD4TB v5 and v6 versions were more sensitive, they had lost some of their specificity over time. Deep learning-based software CAD4TBv6 was published in 2018 and is based on this principle. It is now possible to process photos of people as young as four years old using CAD4TBv6, as opposed to 16 years in prior versions, which had a lower age restriction

of 16 years [22]. It was necessary to have a DICOM image format, as well as the capacity to process photographs of people who were at least four years old, as well as the ability to process images from a CR or DX source in CAD4TB software (scanned films are not acceptable).

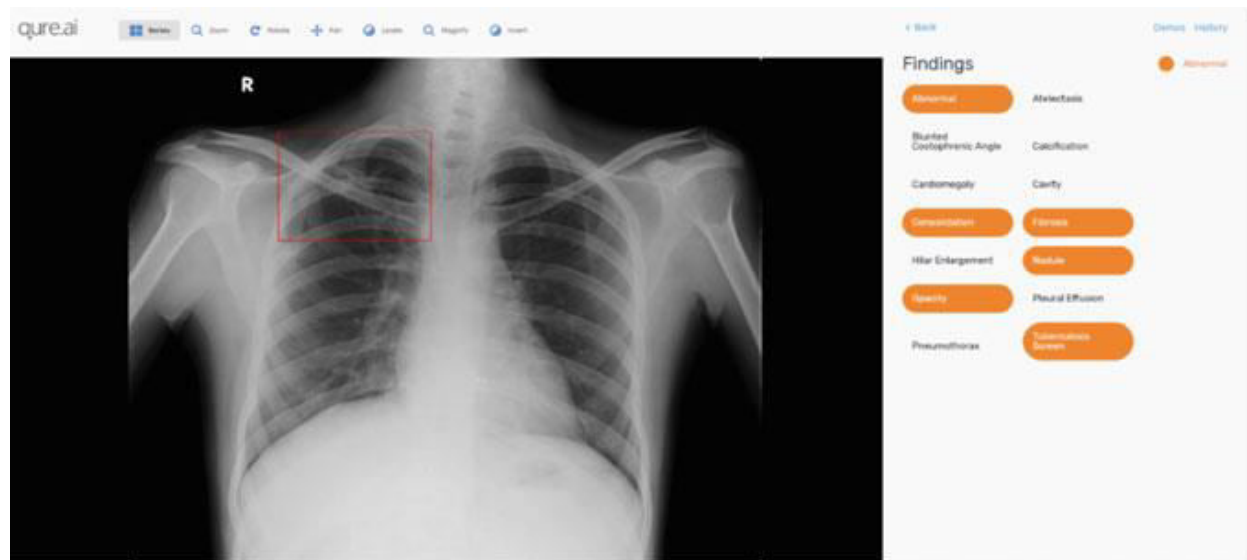

Fig. 3 qXR software output image with abnormalities

qXR

For speedy and reliable illness detection, Qure.ai is an artificial intelligence-based start-up firm established in India that uses machine learning and deep learning technologies. Consolidation, cardiomegaly, pulmonary, cavity, and hilar enlargement, as well as pleural tuberculosis, are all detectable on a chest X-ray using qXR [23]. An Indian CAD programme qXR (Qure.ai, Mumbai, India) was used to evaluate the diagnosis accuracy of a reference standard of microbiologically proven tuberculosis (TB). QXR software's output to the DICOM chest X-ray picture is shown in Figure 3. All X-ray machine types are supported by the qXR software, which can handle a wide range of X-ray pictures of various quality and exposure. In 2018, qXR, a commercial CAD programme, was CE-certified [25]. qXR software is used to identify TB in India's public health screening programme. Microbiologically verified PTB was detected by qXR with a receiver operating characteristic (ROC) curve AUC of 0.81. The AUC for the other anomalies varied from 0.75 to 0.94. Using a radiologist as a reference, the qXR programme attained an AUC of 0.87. The AUC was bigger than the qXR for the most recent version of CAD4TB.

5 Lunit INSIGHT CXR

Consolidation, nodule, calcium calcification, fibrous tissue, pneumothorax, pneumoperitoneum, atelectasis and cardiomegaly are among 10 abnormalities that may be detected by Lunit INSIGHT CXR 3 by screening on the chest X-ray picture. The CE mark appears on Lunit INSIGHT [26]. Figure 4 displays the final JPG pictures (various abnormality scores

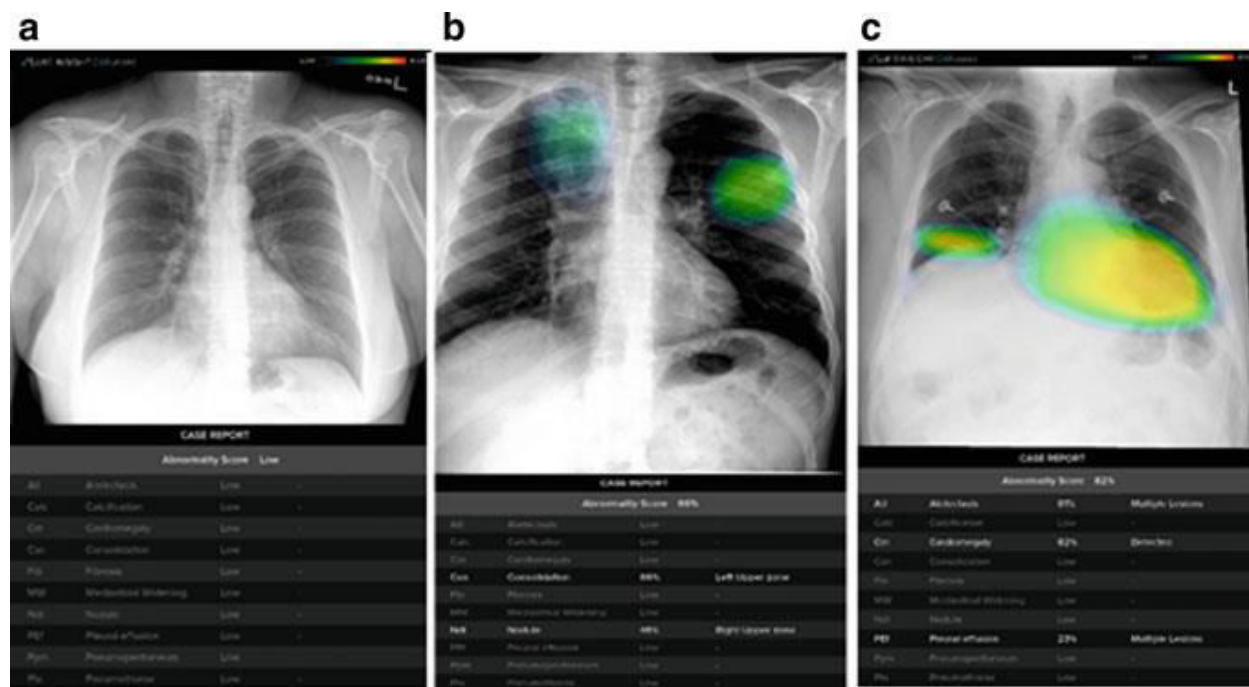


Fig. 4 Lunit INSIGHT CXR 3 software output JPG format images for DICOM chest X-ray images.

Lunit INSIGHTCXR3 software was used to upload DICOM Chest X-ray Images to generate three images (a) a normal image, b) a nodule with an abnormality score of 66%, and c) an image with an abnormality score of 82%. For the purpose of detecting TB-associated anomalies in chest X-ray pictures, the researchers in Qin et al. [27] investigated three deep learning systems, including CAD4TB, qXR, and Lunit INSIGHT. The three DL systems were assessed side by side by the authors. They are all from version 4.7.2 of the Lunit INSIGHT software that Lunit used to create the chest X-ray picture (South Korea). Lunit and CAD4TB can read CXR pictures in the DICOM format. The result of CAD4TB was in the anomaly score range of 0 to 100 for the identification of tuberculitits. qXR and Lunit revealed cavitation, nodule, pneumothorax, and other pulmonary abnormalities in the CXR picture. Deep learning-based softwares CAD4TB,

qXR, and Lunit surpassed experienced human readers in distinguishing between patients with and without tuberculosis.

6 TimBre

Under the telemedicine umbrella, Docturnal is a non-invasive point-of-care diagnosis and screening tool for TB and diabetic retinopathy. Docturnal is a privately held company that created the TB screening software TimBre. This programme simplifies the process of detecting tuberculosis [28]. Medical professionals had to use a microphone array to capture the cough of a patient, along with clinical data such as demographic information, living with TB, pre-existing health issues and family history of TB, sleep and cough patterns, and HIV that were sent to the TimBre app. Using machine learning, the tape was then analysed in real time to determine whether it was positive for tuberculosis (TB). If a person's screening results are positive, a chest X-ray is often advised by physicians to make a diagnosis. When compared to current TB testing technologies, TimBre's app achieved an accuracy rate of 85%. A few chest hospitals in Hyderabad and Narayana Hrudayala in Bangalore are now testing TimBre as an experimental initiative.

7 Discussion

Pre-screening approaches in low-income countries rely on deep learning-based software tools that can accurately diagnose tuberculosis from CXR pictures. For TB detection, there are a variety of software, datasets, and performance indicators, as shown in Table 1. The AUC shortened as "The Area Under a Receiver Operating Characteristic (ROC) Curve," sensitivity (SN), and specificity are the performance indicators utilised for TB detection by different writers in their publications (SP).

8 Conclusion

Automated TB screening using CXRs and deep learning-based CAD systems may allow for a more comprehensive diagnosis. For TB screening in large-population regions, deep learning-based CAD systems can categorise numerous normal CXRs with good sensitivity [34]. These CAD technologies might reduce the cost of radiographic TB testing. CAD methods for TB

diagnosis may be made more more precise and particular by future development on deep learning-based screening systems [35].

References

- [1] K. Paquette, M.P. Cheng, M.J. Kadatz, V.J. Cook, W. Chen, J.C. Johnston, Chest radiography for active tuberculosis case finding in the homeless: a systematic review and meta-analysis. *Int. J. Tuberc. Lung Dis.* **18**(10), 1231–1236 (2014). <https://doi.org/10.5588/ijtld.14.0105>
- [2] J.Y. Wu et al., The role of chest radiography in the suspicion for and diagnosis of pulmonary tuberculosis in intensive care units. *Int. J. Tuberc. Lung Dis.* **13**(11), 1380–1386 (2009)
- [3] C. Schaefer-Prokop, U. Neitzel, H.W. Venema, M. Uffmann, M. Prokop, Digital chest radiography: an update on modern technology, dose containment and control of image quality. *Eur. Radiol.* **18**(9), 1818–1830 (2008). <https://doi.org/10.1007/s00330-008-0948-3>
- [4] M. Bigelow et al., Integrating AI into radiology workflow: levels of research, production, and feedback maturity **7**(1) (2020). <https://doi.org/10.1117/1.JMI.7.1.016502>
- [5] M.A. Khan et al., Lungs cancer classification from CT images: an integrated design of contrast based classical features fusion and selection. *Pattern Recogn. Lett.* **129**, 77–85 (2020). <https://doi.org/10.1016/j.patrec.2019.11.014>
- [6] S. Wang, R.M. Summers, Machine learning and radiology. *Med. Image Anal.* **16**(5), 933–951 (2012). <https://doi.org/10.1016/j.media.2012.02.005>
- [7] GauthamA, BhatejaV, Tiwari A, Satapathy SC(2018) An improved mammogram classification approach using back propagation neural network. *Data Eng. Intell. Comput.* **542**, 283–291 (2018). <https://doi.org/10.1007/978-981-10-3223-3>
- [8] V. Bhateja, M. Misra, S. Urooj, Non-linear polynomial filters for edge enhancement of mammogram lesions. *Comput. Methods Programs Biomed.* **129**, 125–134 (2016). <https://doi.org/10.1016/j.cmpb.2016.01.007>
- [9] V.P. Vianna, Study and development of a computer-aided diagnosis system for classification of chest X-ray images using convolutional neural networks pre-trained for ImageNet and data augmentation 1–7 (2018)
- [10] H. Greenspan, B. Van Ginneken, R.M. Summers, Guest editorial deep learning in medical imaging: overview and future promise of an exciting new technique. *IEEE Trans. Med. Imaging* **35**(5), 1153–1159 (2016). <https://doi.org/10.1109/TMI.2016.2553401>
- [11] L. Pigou, S. Dieleman, P.J. Kindermans, B. Schrauwen, Sign language recognition using convolutional neural networks, in *Lecture Notes in Computer Science. Lecture notes in artificial intelligence. Lecture notes in bioinformatics*, vol. 8925 (2015), pp. 572–578. https://doi.org/10.1007/978-3-319-16178-5_40
- [12] WHO/UNITAID, *Tuberculosis Diagnostics Technology and Market Landscape* (UNITAID Secr. World Health Organization, 2014)
- [13] P. Maduskar, M. Muyoyeta, H. Ayles, L. Hogeweg, L. Peters-Bax, B. Van Ginneken, Detection of tuberculosis using digital chest radiography: automated reading vs. interpretation by clinical officers. *Int. J. Tuberc. Lung Dis.* **17**(12), 1613–1620 (2013). <https://doi.org/10.5588/ijtld.13.0325>
- [14] L. Hogeweg, C. Mol, P.A. De Jong, R. Dawson, H. Ayles, B. Van Ginneken, Fusion of local and global detection systems to detect tuberculosis in chest radiographs, in *Lecture*

- Notes in Computer Science. Lecture notes in artificial intelligence. Lecture notes in bioinformatics, vol. 6363, LNCS, No. Part 3 (2010), pp. 650–657. https://doi.org/10.1007/978-3-642-15711-0_81
- [15] M. Muyoyeta et al., The sensitivity and specificity of using a computer aided diagnosis program for automatically scoring chest X-rays of presumptive TB patients compared with Xpert MTB/RIF in Lusaka Zambia. PLoS ONE **9**(4), 16–18 (2014). <https://doi.org/10.1371/journal.pone.0093757>
- [16] M. Muyoyeta et al., Digital CXR with computer aided diagnosis versus symptom screen to define presumptive tuberculosis among household contacts and impact on tuberculosis diagnosis. BMC Infect. Dis. **17**(1), 1–8 (2017). <https://doi.org/10.1186/s12879-017-2388-7>
- [17] A. Steiner et al., Screening for pulmonary tuberculosis in a Tanzanian prison and computer-aided interpretation of chest X-rays. Public Health Action **5**(4), 249–254 (2015). <https://doi.org/10.5588/pha.15.0037> Deep Learning-Based Software Tools for Tuberculosis Detection... 223
- [18] R.H.H.M. Philipsen et al., Automated chest-radiography as a triage for Xpert testing in resource-constrained settings: a prospective study of diagnostic accuracy and costs. Sci. Rep. **5**(March), 1–8 (2015). <https://doi.org/10.1038/srep12215>
- [19] J. Melendez et al., An automated tuberculosis screening strategy combining X-ray-based computer-aided detection and clinical information. Sci. Rep. **6**(October 2015), 1–8 (2016). <https://doi.org/10.1038/srep25265>
- [20] J. Melendez, R.H.H.M. Philipsen, V. Sunkutu, N. Kapata, Automatic versus human reading of chest X-rays in the Zambia National Tuberculosis Prevalence Survey **21**(April), 880–886 (2017)
- [21] K. Murphy et al., Computer aided detection of tuberculosis on chest radiographs: an evaluation of the CAD4TB v6 system (2019), pp. 1–11 [Online]. Available: <https://arxiv.org/abs/1903.03349>
- [22] Our Improved CAD4TB Software is Now Reliable for Children | Delft Imaging. <https://www.delft.care/cad4tb6/>
- [23] Qure.ai Chest X Ray Study. <https://qure.ai/qxr/>
- [24] M. Nash et al., Deep learning, computer-aided radiography reading for tuberculosis: a diagnostic accuracy study from a tertiary hospital in India. Sci. Rep. **10**(1), 1–10 (2020). <https://doi.org/10.1038/s41598-019-56589-3>
- [25] Qure.ai | qXR Becomes First AI-Based Chest X-ray Interpretation Tool to Receive CE Certification. <https://qure.ai/news/2018/05/31/qXR-CE.html>
- [26] Lunit INSIGHT for Chest Radiography. <https://insight.lunit.io/cxr/>
- [27] Z.Z. Qin et al., Using artificial intelligence to read chest radiographs for tuberculosis detection: a multi-site evaluation of the diagnostic accuracy of three deep learning systems. Sci. Rep. 1–10 (2019). <https://doi.org/10.1038/s41598-019-51503-3>
- [28] TimBre | Docturnal. <https://www.docturnal.com/products/timbre/>
- [29] M. Breuninger et al., Diagnostic accuracy of computer-aided detection of pulmonary tuberculosis in chest radiographs: a validation study from sub-Saharan Africa. PLoS One **9**(9) (2014). <https://doi.org/10.1371/journal.pone.0106381>
- [30] M.T. Rahman et al., An evaluation of automated chest radiography reading software for tuberculosis screening among public- and private-sector patients. Eur. Respir. J. **49**(5) (2017). <https://doi.org/10.1183/13993003.02159-2016>

- [31] S. Mohammad, A. Zaidi, S.S. Habib, B. Van Ginneken, Evaluation of the diagnostic accuracy of computer-aided detection of tuberculosis on chest radiography among private sector patients in Pakistan. *Sci. Rep.* (July), 1–9 (2018). <https://doi.org/10.1038/s41598-018-30810-1>
- [32] J. Melendez et al., Accuracy of an automated system for tuberculosis detection on chest radiographs in high-risk screening. *Int. J. Tuberc. Lung Dis.* **22**(5), 567–571 (2018). <https://doi.org/10.5588/ijtld.17.0492>
- [33] R.C. Koesoemadinata et al., Computer-assisted chest radiography reading for tuberculosis screening in people living with diabetes mellitus. *Int. J. Tuberc. Lung Dis.* **22**(9), 1088–1094 (2018). <https://doi.org/10.5588/ijtld.17.0827>
- [34] M.H. Id et al., A systematic review of the diagnostic accuracy of artificial intelligence-based computer programs to analyze chest X-rays for pulmonary tuberculosis 1–19 (2019)
- [35] P. Putha et al., Can artificial intelligence reliably report chest X-rays? Radiologist validation of an algorithm trained on 2.3 million X-rays 1–13 (2018). [Online]. Available: <https://arxiv.org/abs/1807.07455>